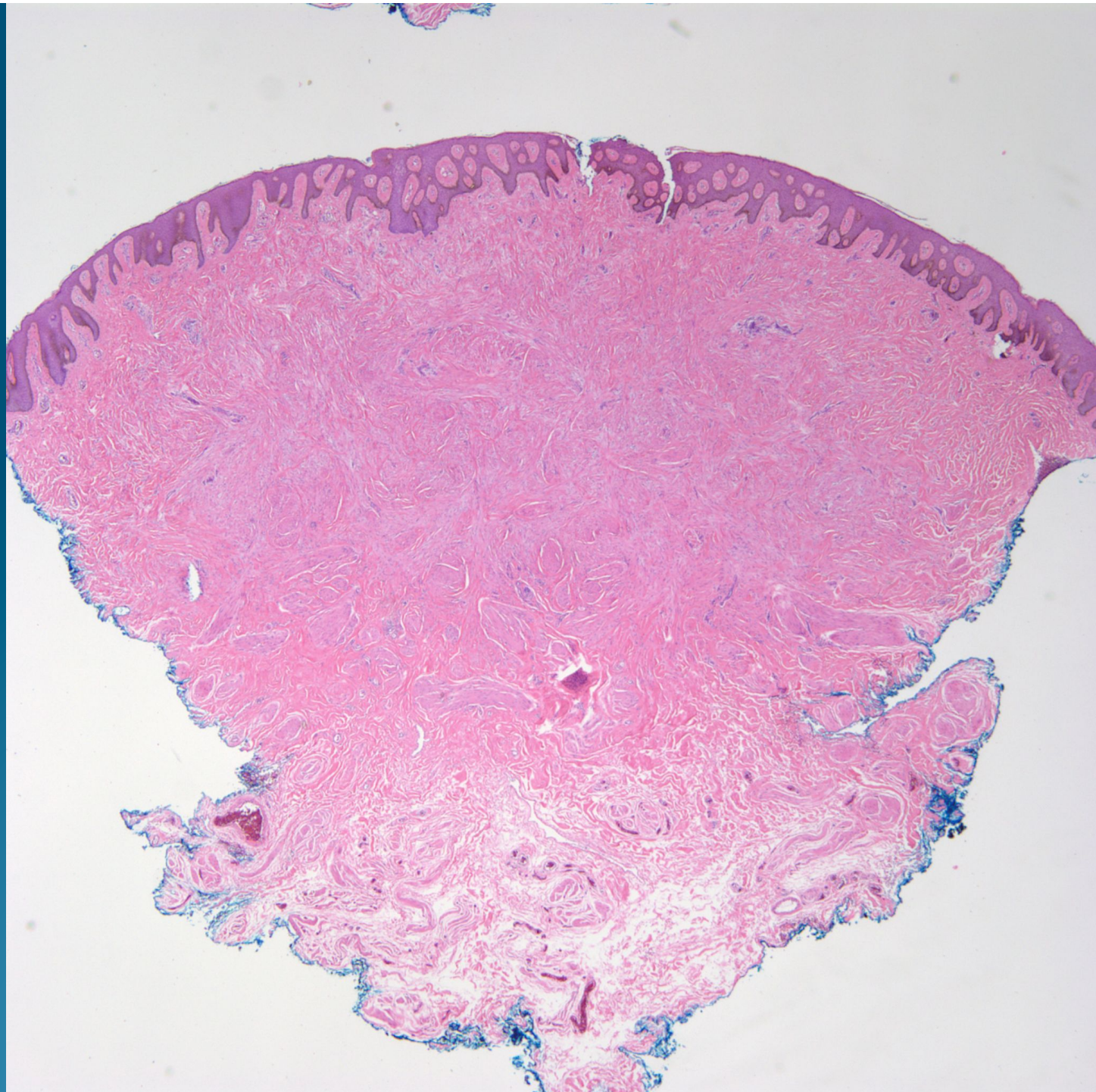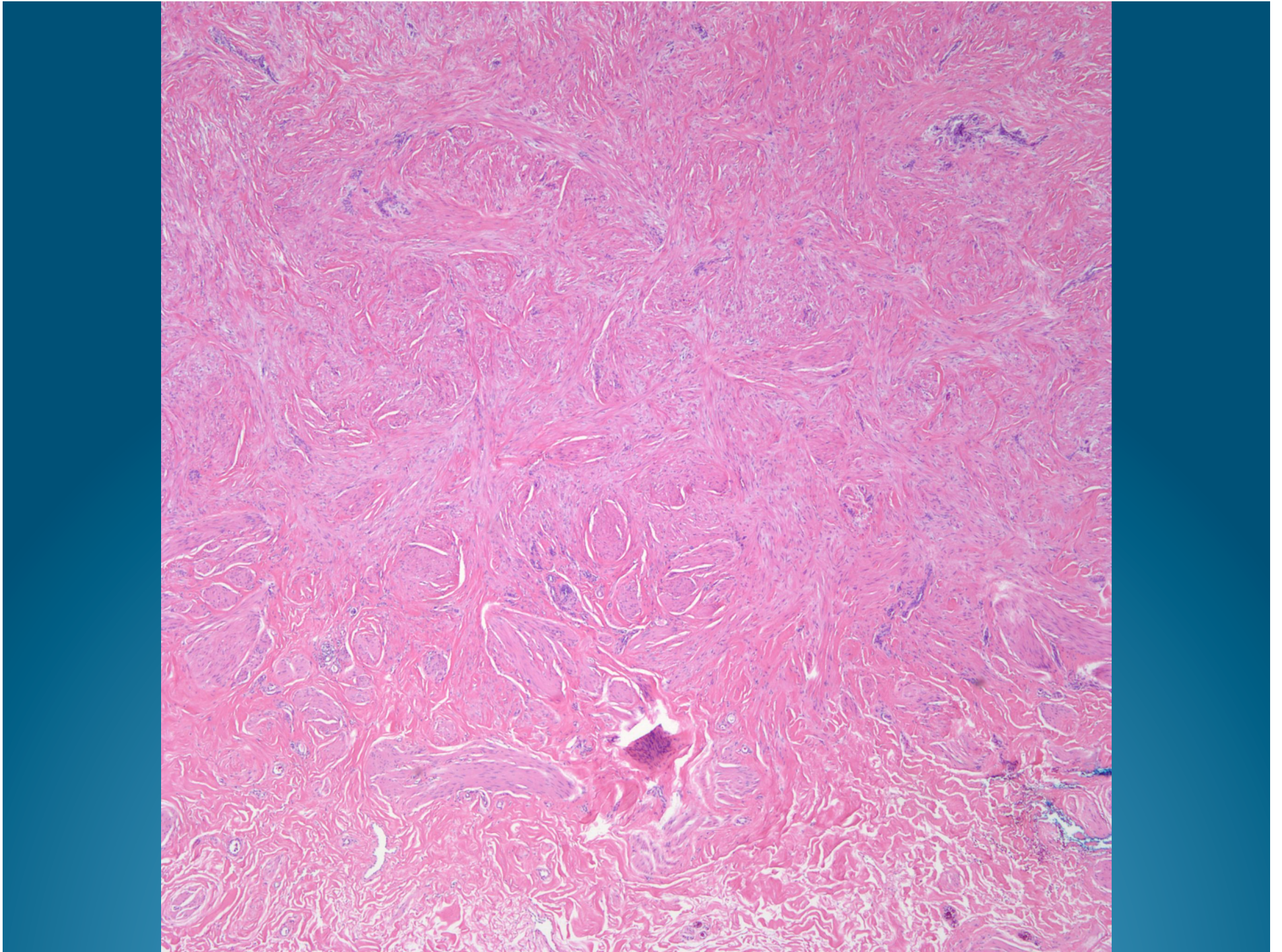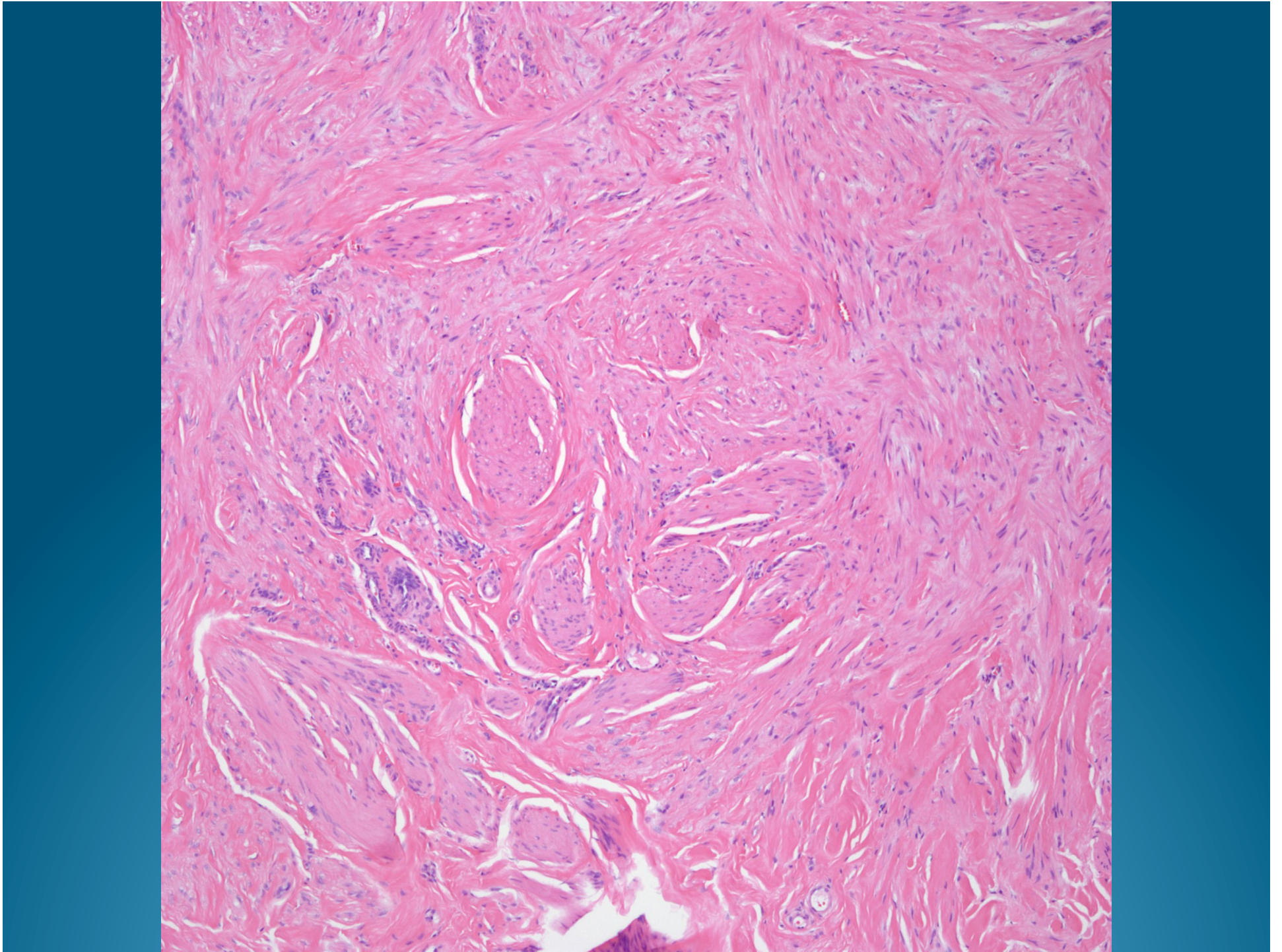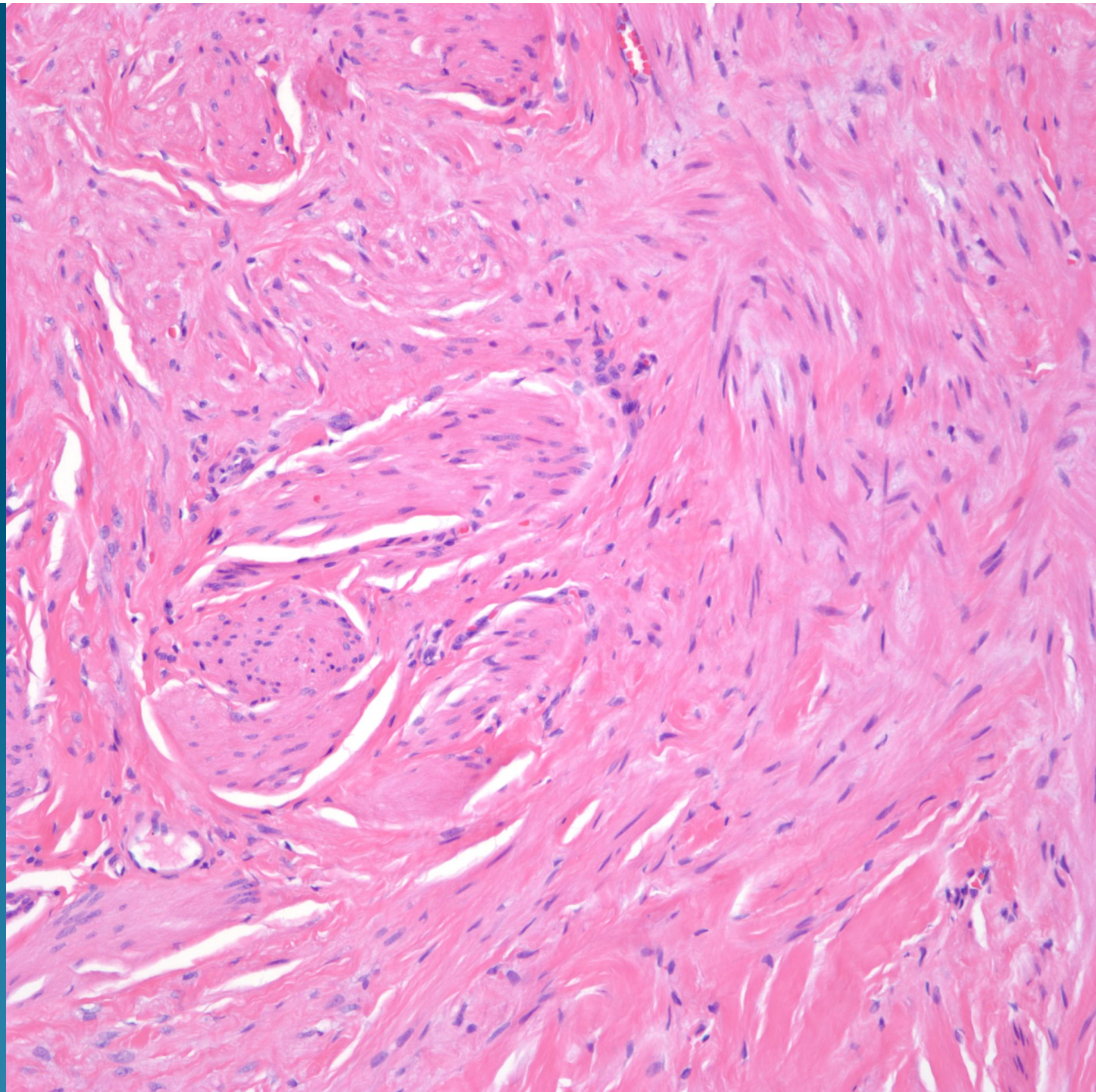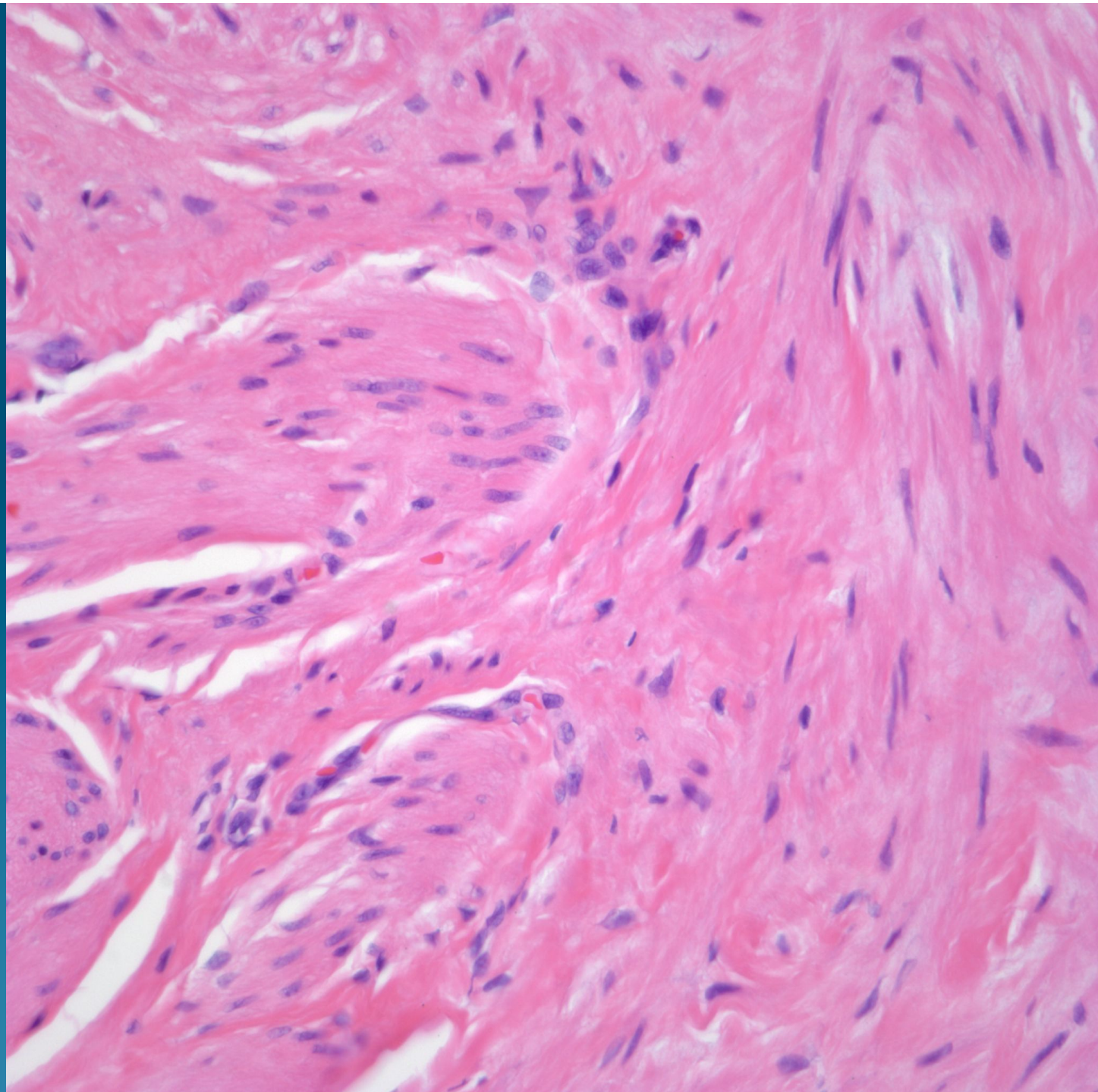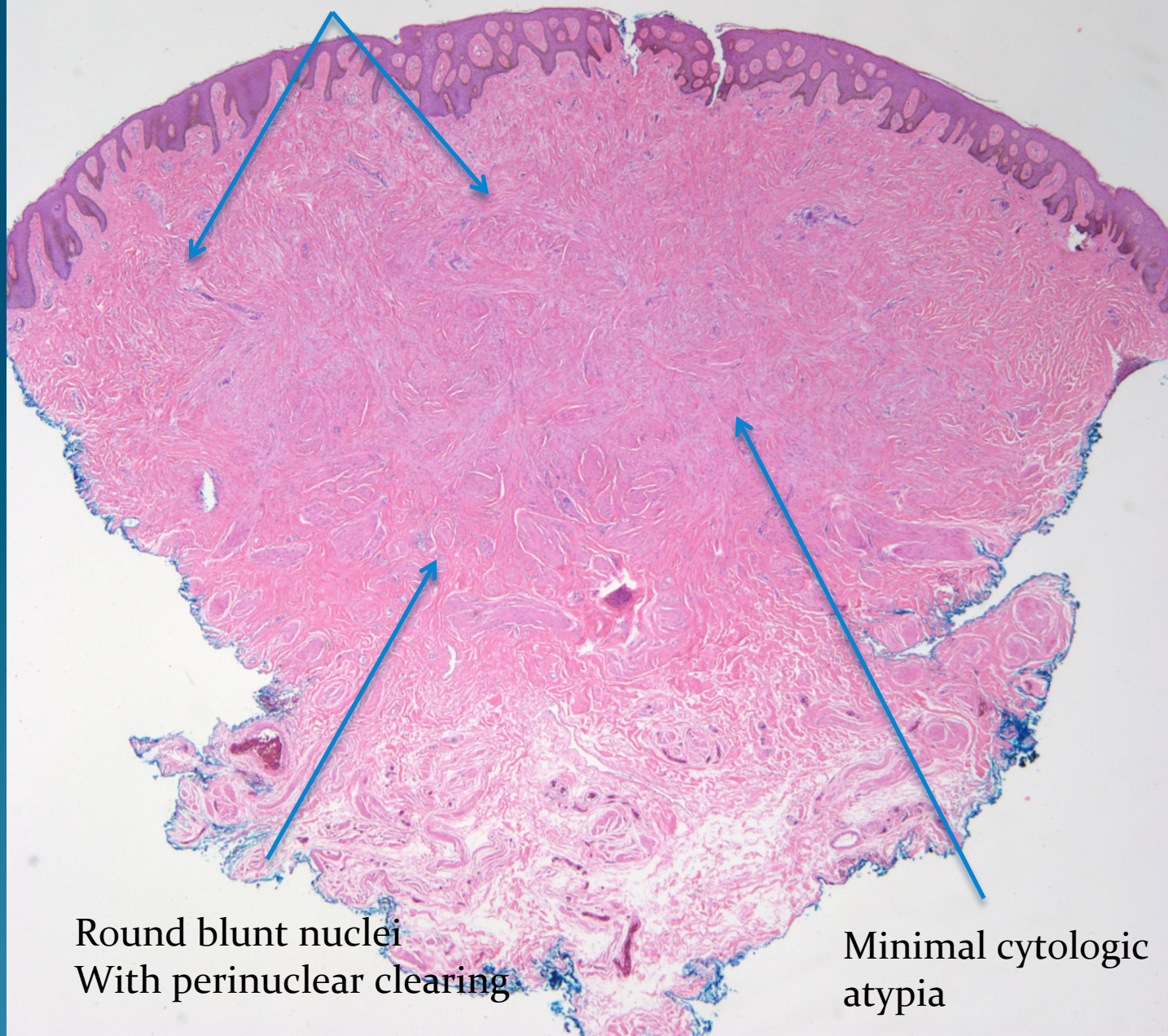


# Cutaneous Leiomyoma



Dermal based spindle cell neoplasm  
With intersecting fascicles



Round blunt nuclei  
With perinuclear clearing

Minimal cytologic  
atypia